

# THE PREVALENCE OF EYE INVOLVEMENTS IN RHEUMATOID ARTHRITIS AND THEIR CORRELATION WITH ANTI-CYCLIC CITRULLINATED PEPTIDE ANTIBODY IN SULAIMANI GOVERNORATE/IRAQ



Rawand Ali Mustafa <sup>a</sup>, Raouf Rahim Mirza <sup>a</sup>, and Hemn Raof Rasool <sup>c</sup>

Submitted: 2/3/2022; Accepted: 7/3/2023; Published: 21/6/2023

## ABSTRACT

### *Background*

Rheumatoid arthritis is a common autoinflammatory disease that affects the joints and causes several extra-articular problems, including ocular involvement, which typically manifests in the anterior ocular region. The anti-CCP has a sensitivity comparable to the rheumatoid factor and higher specificity for identifying the disease.

### *Objectives*

To estimate the prevalence of eye involvements in Rheumatoid arthritis and their correlation to the anti-cyclic citrullinated peptide antibody.

### *Patients and Methods*

A cross-sectional study of 121 patients who satisfied the 2010 ACR/EULAR RA Classification Criteria (6/10 or more points) were between 18 and 60. After establishing a patient's medical history and physical examination, blood samples were collected to test for anti-CCP antibodies, and an eye exam was conducted.

### *Results*

There were significantly more females than males; 104 (86%) were female, and 17 (14%) were males. The median age was 47(42–53.5) years. The median disease duration was 4(2–10) years. The mean disease activity was  $3.86 \pm 1$ , and the median anti-cyclic citrullinated antibody titers were 29.18(16.75–133.35) U/ml. The overall eye complications typical of Rheumatoid arthritis were observed in 37 (30.6%) and 84 (69.4%) without eye involvement. Dry eyes were the most frequent eye complaint (29.8%). One instance with episcleritis (0.8%). One with filamentary keratitis (0.8%). Anterior uveitis was detected in two cases (1.7%). Eye involvement correlated with anti-cyclic citrullinated peptide antibody (P- value 0.004).

### *Conclusion*

Eye manifestations of rheumatoid arthritis were a prominent part of extra-articular manifestation. The dry eye was the most apparent manifestation, and they correlated to the anti-CCP antibody.

**Keywords:** *Rheumatoid Arthritis, Episcleritis, anti-CCP antibody, ocular manifestation, dry eye.*

<sup>a</sup> Sulaymaniyah Directory of Health, Sulaimani, Kurdistan Region, Iraq.

Correspondence: [rawandrama@yahoo.com](mailto:rawandrama@yahoo.com)

<sup>b</sup> College of Medicine, University of Sulaimani, Kurdistan Region, Iraq.

<sup>c</sup> Shaheed Aso Eye Hospital, Sulaymaniyah Directory of Health, Ministry of Health, Kurdistan Region, Iraq.

## INTRODUCTION

Since ancient times, Rheumatoid arthritis (RA) has been a medical problem. In 1800, Landre-Beauvais documented the illness, but earlier paintings represented rheumatic joints. Since the middle of the previous century, there have not been any notable dissections in the types of disease. Since that time, however, the standard presentation and classification criteria for RA have evolved<sup>(1)</sup>. RA is a complex autoimmune illness that predominantly affects joints<sup>(2,3)</sup>. It is distinguished by progressive, symmetric inflammation of the afflicted joints, which leads to cartilage degradation, bone erosion, and disability<sup>(3)</sup>.

Many experts have studied RA's epidemiology and incidence during the past three decades. According to these studies, RA can affect people of any race, ethnicity, nationality, and age<sup>(2)</sup>. It primarily affects the elderly. It occurs more frequently in females than males (female-to-male ratio 3:1)<sup>(4)</sup>. The stated prevalence ranged from 0.5 to 1%, with geographical variance<sup>(4-6)</sup>. The incidence decreases from north to south (in the northern hemisphere) and urban to rural locations. Specific Native American populations have an exceptionally high incidence<sup>(5)</sup>.

Rheumatoid factor (RF) has been used for decades to diagnose RA. RF is an antibody directed against the Fc segment of immunoglobulin G. Waaler, and Rose originally reported RF in 1940. Pike claimed in 1949 that it could be used as a diagnostic criterion for RA<sup>(7)</sup>. Anti-cyclic citrullinate (Anti-CCP) antibody, a more recent test for anti-citrullinated protein antibody (ACPA), is comparable in sensitivity but more specific than the RF test (exceeding 95% of diagnostic specificity and 83% of sensitivity)<sup>(8)</sup>. Anti-CCP antibodies recognise peptides in which arginine has been converted to citrulline by peptidyl arginine deaminase, found in inflammatory synovium and mucosal tissues<sup>(9)</sup>. Anti-CCP is closely linked with a more severe course of the disorder and can be detected in asymptomatic patients years before the development of RA<sup>(9-11)</sup>. Since 2010, Anti-CCP has been added as a criterion in the ACR/EULAR guidelines for the classification of RA<sup>(12,13)</sup>.

Due to the disease's chronic, inflammatory and autoimmune characteristics may develop extra-articular symptoms and comorbidities<sup>(14)</sup>. Ocular symptoms are a considerable proportion of extra-articular symptoms in RA<sup>(15)</sup>. Eye complications from RA are commonly underestimated and misdiagnosed. However, These conditions mainly impact the eye's anterior chamber

and result in dry eye, episcleritis, scleritis, peripheral ulcerative keratitis, and uveitis<sup>(16)</sup>. These concomitant visual signs are crucial and should be addressed due to the significant risk of permanent damage and blindness<sup>(17)</sup>.

This study aims to determine the significance and frequency of RA eye impairments and the relation between these impairments and anti-cyclic citrullinated peptide antibodies found in a patient's blood, which is essential to manage the disease properly.

## PATIENTS AND METHODS

A cross-sectional study of 121 RA patients visited the Rheumatology and Rehabilitation Consultation Center in Sulaymaniyah governorate, Iraq, monthly for treatment and follow-up from October 2021 to July 2022. After asking the patients and obtaining oral agreements, patients were enrolled on the research. The Sulaymaniyah School of Medicine Ethics Committee approved the study.

### Inclusion criteria

Patients who met the fulfillments of the 2010 American College of Rheumatology (ACR) and European League Against Rheumatism (EULAR) RA Classification Criteria (6/10 or more points)

### Exclusion criteria

- Patients under 18 and above 60, Hypo or hyperthyroid,
- History of radiation exposure.
- Patients who did eye operations or with contact lenses
- Overlap Syndromes with other connective tissue diseases like systemic lupus erythematosus (SLE).

The age, gender, and other social and demographic information were first collected. Disease activity was assessed using a disease activity score of 28 (28 joints +28 tender joints +Physicians global assessment +Erythrocyte sedimentation rate) after a complete medical history and physical examination. Blood samples were taken concisely for Rheumatoid factor (RF), Erythrocyte sedimentation rate (ESR), and Anti-CCP antibodies with the eye examination.

Rheumatoid factor (RF) was detected in serum using the agglutination principle (Latex fixation tests). Anti-CCP ELISA kit (AESKU.DIAGNOSTICS. Ref

3206,55234 Wendelsheim, Germany) was used for the quantitative detection of anti-cyclic citrullinated antibody to immunoglobulin G (IgG) antibodies in the patient's serum by indirect enzyme-linked immunosorbent assay (ELISA). A result of less than 20 is regarded as negative. (Negative: < 20U/ml, Positive  $\geq$  20U/ml) based on the manufacturer's guidelines.

### **Eye examination**

During the ocular inspection, 242 eyes of 121 individuals were evaluated using a slit lamp of the anterior compartment, air puff tonometry for intraocular pressure, Snellen vision tests for visual acuity, and indirect funduscopy. Schirmer's test was performed with a disposable Whatman filter paper No 41 calibrated strip (5 mm width x 41mm length) scaled from zero to 38 mm (tear touch blue) with a minimum count of 1 mm. It has a round blunt tip with a blue line from the tip to the 5mm mark. Blue dye (foods, drugs, cosmetics Blue No.1) permeates the scale, making it easier to see while monitoring tear production. The manufacturer individually packs each strip in its pouch. The examiner Measured the tear-soaked strip after 5 minutes, and Schirmer strip wetness below 15 mm suggests dry eyes and (0 to 5 mm), (5 to 10 mm), (10 to 15 mm ) regarded as severe, moderate, and mild respectively. Fluorescein Sodium Ophthalmic Strips were used to stain the ocular surface to detect the corneal and conjunctival epithelium damage caused by dryness. Based on a clinical examination, the ophthalmologist diagnosed scleritis and episcleritis. The fundoscopic investigation discovered any complaints of the posterior part.

The appropriate software was applied for the statistical analysis (Statistical Package for Social Sciences for Windows version 26.0). The observations of the continuous measurements were provided as the mean accompanied by the standard deviation, whereas the outcomes of the categorical data were as a number. The Fisher's Exact test for categorical parameters and the unpaired t-test for continuous (scale) parameters were employed to examine the significance of variations in research parameters between the two groups. Both tests were run independently. A significant difference was determined as a p-value of < 0.05.

## **RESULTS**

A total of 121 patients participated and were evaluated. One hundred four female patients (86%) and 17 male patients (14%), demonstrating that females

outnumbered males. As seen in Table 1, A mean and standard deviation were used to describe data that followed a normal distribution. However, a median and interquartile range were used to represent data that did not (IQR). The median age of the patients was 47, with an interquartile range of (42-53.5) years. Both newly diagnosed RA and RA were present for a long time (median disease duration of four years, interquartile range (2-10) years). The median anti-CCP antibody titers were 29.18 with an interquartile range of (16.75-133.35) U/ml, the patients' median ESR was 35 with an interquartile range of (19-56.5), the median patient's global assessment was 30 with an interquartile range of (20-47.5), and the patient's evaluation indicated that the mean disease activity was 3.88 ( $\pm$ 1) (moderate disease activity) with DAS28+ ESR.

Despite the age inclusion criteria of (18-60) years, the minimum age was 20 years, and the maximum was 60 years. They were grouped by age intervals, as illustrated in Table 2; just over half (52.1%) were between 41 and 50, and a third (33.9%) fell within the 51–60 age range. Only three (2.5 %) were in their twenties (20-30). There were 14 cases between the ages of 31 and 40, representing 11.6% of the total. Most patients were above forty (86%), whereas only 17 (14%) were younger than forty.

The disease activity of the participants was determined with the use of DAS28+ESR, as shown in Table 3, only 15 (12%) of the patients were in remission, while 106 (88%) had active disease. Seventy-eight of the entire 121 individuals had moderate disease activity (65%), eighteen patients had low disease activity (15%), and ten cases had high disease activity (8%). According to DAS 28 +ESR scores, one hundred-six out of 121 patients had active disease, whereas only 15 were in remission.

The prevalence of anti-CCP and RF in the population studied is depicted in Figure 1. Anti-CCP antibody results were positive in 75 (62%) patients and negative in 46 (38%). In terms of RF, nine cases were missing for RF. In the remaining 112 cases, 64(57.1%) patients tested positive for RF and 48(42.9%) patients tested negative for RF.

The inflammatory eye manifestations associated with RA are shown in Table 4. There were 37 (30.6%) individuals with one or two eye manifestations, while 84 (69.4%) patients had none. The most prevalent complaint was dry eyes, detected in 36 (29.8%) 121

patients. The patients with dry eyes were classified into three groups based on the of Schirmer's test, Table 4.

Overall, there were nine cases of moderate dry eye (7.4%), Twenty-three cases of mild dry eye (19%), and only four cases of severe dry eye (3.3%). Scleritis was not observed in any of the assessed patients, while there was one episcleritis (0.8% of total cases). A single instance of filamentary keratitis (0.8% of all cases) was identified. Old anterior uveitis was identified in two individuals, accounting for 1.7% of all patients. 31 patients had a single manifestation (26%), and six had two manifestations (5%). Among the individuals with two manifestations, dry eye was one of the manifestations. The episcleritis patient, as well as one of the uveitis patients, experienced mild dry eye. The patient with filamentary keratitis had a severe dry eye. Out of the two people who were diagnosed with uveitis, only one of them experienced dry eye symptoms Table 4.

Relation of eye involvement to the other variables of the participants:

Thirty of the thirty-seven cases with eye manifestations were anti-CCP positive, while only six were negative; among patients without eye involvement, 45 were positive, and 40 were negative Table 5. Eye manifestations were more among patients with positive anti-CCP antibodies. The correlations between categorical data (positive versus negative for anti-CCP antibody and presence versus absence of eye symptoms) were assessed using Chi-square analysis and Fisher's exact test, and it was very significant with a P- the value of 0.004 (<0.05).

The relation of each ocular inflammatory manifestation with the presence of Anti-CCP antibody is shown in Table 6. Anti-CCP antibodies were detected positive in 29 dry eye cases. There were also two cases of uveitis and one case of episcleritis. In contrast, only seven incidences of dry eyes were in the negative group. Thirty of the 37 individuals with eye manifestations tested positive for anti-CCP antibodies. Seven were detected in the group with negative anti-CCP antibodies, Table 6.

The relationship between inflammatory ocular manifestations and the Rheumatoid factor in 112 participants with valid RF was illustrated in Table 7. There were 39 patients with negative RF tests and the same number with positive RF tests in the group without ocular signs. In contrast, nine patients tested

negative, and 25 tested positive in the group with ocular manifestations. Nine instances were missing for RF, and a cross-tabulation of the remaining 112 participants revealed 34 cases with inflammatory ocular manifestations and 78 without manifestations. There was a statistically significant relationship between the manifestations and RF positivity among the 112 participants, with a P-Value of 0.02 (<0.05). Pearson Chi-Square was employed to evaluate the relationship.

Table 8, anti-CCP antibody titers in the group with ocular manifestation were on a median of 70.12 U/ml. In contrast, titers in the group without manifestations were on a median of 22.69 U/ml. For all patients, the median anti-CCP antibody titer was 29.18 U/ml. The median anti-CCP antibody titers in the group with inflammatory ocular manifestations were significantly higher than in the group without. Anti-CCP antibody titer was shown to have a statistically significant relation with eye manifestations, as revealed by a P-value of 0.009(<0.05).

There was also a significant association between the age of the patients and the ocular manifestation, with a P-value of 0.026(<0.05). The median age of the group without eye manifestations was 46 years, whereas the median age of the group with eye manifestations was 50 years. The median sample age was 47 years old. Inflammatory ocular manifestations increased and were more frequently observed in the older age group.

No statistically significant relationship was seen between ocular involvement and disease duration (P-value =0.244), Erythrocyte sedimentation (P-value =0.204), or Disease Activity Score 28 (P- value =0.342) (all values >0.05). The Mann-Whitney U-Test was used for all assessments. However, the Independent-Samples T-Test was only used to investigate the relationship between disease activity and Ocular manifestations Table 8.

Table 1. Characteristics and parameters of RA patients included in the study.

Parameters	Median	Interquartile range (IQR)	Mean	Standard deviation	Distribution of data
Age of the patients(year)	47	42–53.5			Not normal
RA duration (year)	4	2–10			
Anti-CCP antibody titers (U/ml)	29.18	16.75–133.35			
Erythrocyte sedimentation rate(mm/hr)	35	19–56.5			
PGA (mm)	30	20–47.5			
<b>Disease activity score 28</b>			<b>3.88</b>	<b>1</b>	<b>Normal</b>

RA: rheumatoid arthritis, anti-CCP: anti-cyclic citrullinated peptide, PGA: patients' global health assessment, ESR: erythrocyte sedimentation rate.

Table 2. Distribution of the participants according to the age groups.

Age groups	No. of patients	%
20-30	3	2.5
31-40	14	11.6
41-50	63	52.1
51-60	41	33.9
<b>Total</b>	<b>121</b>	<b>100</b>

Table 3. Distribution of the participants according to the disease activity score by DAS28+ESR.

Disease activity		No. of the patients	%
<b>Remission</b>	< 2.6	15	12
<b>Low</b>	≥ 2.6 but ≤ 3.2	18	15
<b>Moderate</b>	> 3.2 but ≤ 5.1	78	65
<b>High</b>	> 5.1	10	8
<b>Total</b>		<b>121</b>	<b>100</b>

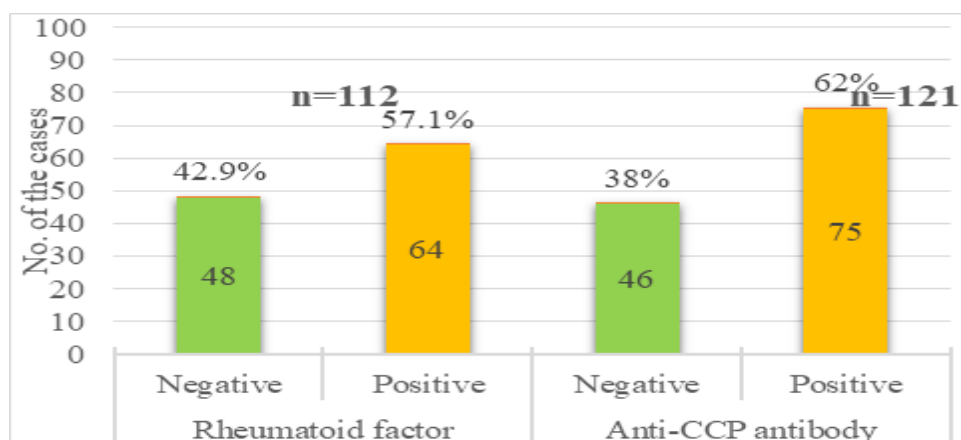


Figure 1. Prevalence of anti-cyclic citrullinated peptide (anti-CCP) antibody and Rheumatoid factor (RF).

Table 4. Ocular inflammatory manifestations associated with Rheumatoid arthritis.

Observations	Count	%
<b>Dry Eye syndrome</b>	36	29.8
Mild	23	19
Moderate	9	7.4
Severe	4	3.3
<b>Episcleritis</b>	1	0.8
<b>Anterior Uveitis</b>	2	1.7
<b>Filamentary keratitis (FK)</b>	1	0.8
<b>Total patients with manifestations</b>	37	30.6
<b>Patients with one manifestation</b>	31	26
<b>Patients with two manifestations</b>	6	5
<b>Total No. of the participants</b>	<b>121</b>	<b>100</b>

Table 5. Inflammatory ocular manifestations \* Anti-CCP Crosstabulation.

Inflammatory ocular manifestations	Anti-CCP		Total	Pearson Chi-Square
	Negative	Positive		
<b>Absent</b>	39	45	84	P- value 0.004
<b>Present</b>	7	30	37	
<b>Total</b>	<b>46</b>	<b>75</b>	<b>121</b>	

Table 6. Relation of each ocular inflammatory manifestation with the presence of Anti-CCP antibody.

Manifestations	Anti-CCP antibody	
	Negative	Positive
<b>Dry Eye syndrome</b>	7	29
<b>Episcleritis</b>		1
<b>Uveitis</b>		2
<b>Filamentary keratitis (FK)</b>		1
<b>Total patients with Eye involvement</b>	<b>7</b>	<b>30</b>

Table 7. Inflammatory ocular manifestations \* Rheumatoid factor Cross-tabulation.

Inflammatory ocular manifestations	Rheumatoid factor		Total	Pearson Chi-Square
	Negative	Positive		
<b>Absent</b>	39	39	78	P- value 0.021
<b>Present</b>	9	25	34	
<b>Total</b>	<b>48</b>	<b>64</b>	<b>112</b>	

**Table 8. Relation of the ocular manifestations to anti-cyclic citrullinated antibody titers, age in years, RA duration, ESR, and disease activity score 28.**

Parameters	Inflammatory ocular manifestations						P-Value
	Absent		Present		Total		
	Mean	Median	Mean	Median	Mean	Median	
<b>Anti-CCP antibody titers (U/ml)</b>		22.69		70.12		29.18	<b>0.009*</b>
<b>Age of the patients(years)</b>		46		50		47	<b>0.026*</b>
<b>RA duration (year)</b>		4		5		4.5	<b>0.244*</b>
<b>ESR (mm/hr.)</b>		30		42		35	<b>0.204*</b>
<b>Disease activity score 28+ESR</b>	3.8	3.86	3.99	4.05	3.86	3.94	<b>0.342**</b>

(\* Independent-Samples Mann-Whitney U Test, (\*\*) Independent-Samples T- Test Asymptotic (2-sided test) significances are displayed. The significance level is 0.05.

## DISCUSSION

Rheumatoid arthritis (RA) is a complex autoimmune illness affecting the synovial lining of the joints, which is the predominant site of the disease pathology. Rheumatoid arthritis's chronic inflammatory and autoimmune components are responsible for developing many systemic symptoms and comorbidities<sup>(14)</sup>. The body will release antibodies that target its tissues, resulting in organ malfunction and damage<sup>(14)</sup>. RA causes several evident extra-articular problems, including ocular involvement, which typically manifests in the anterior ocular region of the eye. The cause is unknown, although inflammation may cause oxidative stress that destroys eye surface epithelium and lacrimal tissue, reducing tear production<sup>(16,18)</sup>.

Collagen and proteoglycans are found in the joints, the sclera and the cornea. This comparable histologic characteristic may be responsible for more than one ocular symptom of RA. The majority of viewpoints support the immunology-based mechanism when discussing the pathophysiology of RA-related ocular diseases. Immune complex deposition, the release of collagenase by macrophages and neutrophils, the creation of cytokines, the activation of complement, and the manufacture of autoantibodies all contribute to autoimmune disorders<sup>(19)</sup>.

This study revealed eye manifestations in 30.6% of the individuals, with dry eyes being the most predominant manifestation, as observed by 29.8%. A dry eye can develop either when the eye does not produce enough tears or when the tears evaporate too quickly, causing the eye to become irritable. The most prominent ocular

involvement of RA is dry eye, and RA is the most frequent autoimmune disease that results in dry eye. Dry eyes in RA may be a clue to secondary Sjögren's syndrome<sup>(20, 21)</sup>. One of the cases had a dry mouth and severe dry eye, and both RF and anti-CCP antibodies were positive. Sjogren syndrome was thought to be present in the patient. However, tests for antinuclear antibodies and salivary gland biopsy results were all negative. Even when sicca manifestations accompany it, having a severe dry eye in RA does not mean the patient has secondary Sjogren's syndrome<sup>(21)</sup>. Dry eye was present in 97% of participants with eye involvement, either as the only manifestation or in addition to other inflammatory ocular manifestations.

In a cross-sectional study of 691 patients in grades I and II (early and moderate progression RA), Zlatanovi et al., 2010, reported eye manifestations in 27.2% and dry eye in 17.65% of the individuals studied, which was comparable to the present study. However, our sample includes people at various RA stages, and more advanced settings are associated with a higher incidence of ophthalmic manifestations<sup>(22)</sup>.

A cross-sectional study by Vignesh and Srinivasan, 2015 examined the eye of 196 RA patients. They found that 39% of the individuals had eye involvement, higher than this study and that 28% had dry eye, almost identical to the present findings<sup>(23)</sup>.

Kaur et al., 2016 conducted a study on 139 RA patients; 38% had signs of RA-related eye disease, and 31% complained of dry eye<sup>(24)</sup>. Additionally, A cross-sectional study by Pegu et al., 2018 on 114 RA patients revealed that 42.1% exhibited ocular involvement, with

dry eyes accounting for 31.5%. It was lightly more than in this study<sup>(25)</sup>.

Furthermore, in a cross-sectional study with 60 patients, Fadhil and Al-Dabbagh, 2017, observed a much higher incidence of ocular symptoms and dry eye, which was 65% and 50%, respectively<sup>(26)</sup>. Despite a small sample size, patients over 60 were included, resulting in a higher mean age when compared to the current study. Changes in the ocular microenvironment with age increase the likelihood of inflammatory ocular surface diseases<sup>(22)</sup>.

This study primarily employed the Schirmer test to classify and identify instances of dry eye. Other tests, such as the Tear film break-up time (TBUT) test, which uses fluorescein dye to evaluate tear film stability, and the Ocular straining score (OSS) test, which uses rose Bengal dye to evaluate the amount of damage done to the ocular surface, have been used to measure tear dryness in other studies. Abd-Allah et al., 2020 employed the Schirmer test, tear film opacity testing, and ocular surface scleral tear test to assess dry eye in 42 RA participants<sup>(21)</sup>. They discovered that 71% of the patients suffered from dry eyes. Compared to our study, the prevalence of dry eye was high; however, the sample size was smaller, and two other diagnostic procedures (TBUT and OSS) were employed in addition to the Schirmer test.

The terminology and techniques used to diagnose dry eye are still up for debate and are continually being modified<sup>(27)</sup>. Nevertheless, despite the diverse methods used for diagnosing and categorising dry eye among the studies, the Schirmer test continues to be regarded as the simplest and most often employed method in the studies.

Episcleritis and scleritis are both types of ocular inflammation with similar acute manifestations. Scleritis is generally more severe, with inflammation extending to the deep scleral covering of the eye, whereas episcleritis is often benign and superficial<sup>(28)</sup>. Scleritis can also cause vision loss and is related to systemic illness in up to 50% of cases<sup>(29)</sup>. Episcleritis is more prevalent in women aged 20 to 40 and resolves without treatment<sup>(28)</sup>. In the current study, there was a case (0.8%) of diffuse Episcleritis in a female patient in her forties; she had a mild dry eye with both RF and anti-CCP positive. Rheumatoid arthritis was the only systemic illness discovered to be a contributing cause in the patient.

Similarly, Pegu et al., 2018 reported one case, despite previous studies reporting a range of 2% to 5%. Scleritis might be the first sign of RA. There were no instances of scleritis during the study. Fadhil and Al-Dabbagh observed the same conclusion 2017; however, scleritis was identified in 2% of patients in earlier research<sup>(23,24,30)</sup>.

The presence of filaments on the corneal surface is known as filamentary keratitis (FK), commonly accompanied by symptoms like a foreign body sensation, discomfort, and eye pain. Dry eye disease is FK's most frequent ocular and systemic condition<sup>(31)</sup>. One patient, or 0.8% of the patients in this study, showed filamentary keratitis. In addition, the patient noticed experiencing dry eyes. Filamentary keratitis is an uncommon condition. Furthermore, Pegu et al., 2018 found 1.7% with FK<sup>(25)</sup>.

Uveitis was this study's second most prevalent condition, with evidence of old anterior uveitis in two cases (1.7%). According to research, anterior uveitis is uncommon in RA, occurring at a prevalence of less than 0.5%<sup>(30,32)</sup>.

Sterile corneal ulcers have been linked to RA. In ordinarily quiet eyes, patients with RA can develop corneal ulcers in the peripheral, paracentral, or central cornea. These ulcers can occasionally be linked to scleritis<sup>(33)</sup>. The study found one paracentral corneal opacity (0.8%) and one mild hazy cornea (0.8%). Corneal haze results from subepithelial corneal fibrosis resulting from a pathological healing process<sup>(34)</sup>. Among the cases evaluated, there was one with glaucoma. Evidence that immunological components are involved in the development of glaucoma is developing as one of the many hypothesised mechanisms for the disease. Patients with glaucoma and RA have autoantibodies and CD4+ T cells contributing to their pathogenesis<sup>(35)</sup>.

Anti-CCP has a sensitivity that is approximately level with that of the RF but a significantly greater specificity when distinguishing RA from other rheumatic disorders. Additionally, in healthy persons and patients with undifferentiated arthritis, the presence of anti-CCP antibodies appears to be a highly reliable predictor of the future establishment of RA<sup>(36)</sup>. Anti-CCP antibodies can be identified in asymptomatic individuals years before the manifestation of RA, and they are connected to a more severe disease advancement<sup>(10)</sup>. This study detected the anti-CCP antibody in 75 out of 121 RA patients, equivalent to a 62% prevalence rate. Anti-

CCP antibodies were shown to be more prevalent in other studies. Payet et al., 2014 found that second-generation anti-CCP (anti-CCP2) was present in 70% of RA patients during an observational and descriptive study on 1162 RA patients<sup>(37)</sup>.

In this study, eye manifestations were more frequent among anti-CCP antibody-positive patients, and there was a statically significant correlation between eye involvement in RA and anti-CCP antibodies. Vignesh and Srinivasan, 2015, investigated this association and revealed high significance. Furthermore, Kaur et al., 2016 and Pegu et al., 2018 found the relation significant. There was also a relation between antibody titers and eye involvement; individuals with higher levels of anti-CCP antibodies in their blood were more likely to experience inflammatory ocular manifestation.

The prevalence of RF was 57.1% among the 112 patients evaluated for RF using the latex agglutination method. The rheumatoid factor in the patient's blood was significantly linked to ocular manifestations with a P-value: 0.021 (< 0.05). Among the 112 people with an RF test, inflammatory ocular manifestation was more common in RF-positive patients than in RF-negative patients. Also, Pegu et al. (2018) discovered a link between ocular manifestations and RF<sup>(25)</sup>.

The cornea and ocular surface, two crucial parts of the visual system, are impacted by ageing, making certain eye disorders more likely to develop. Dry eye syndrome is one of these conditions that cause alterations to the tear film. According to studies, dry eye illness affects 14.4% of Americans over 50, with the incidence rate rising with age and being more common in females<sup>(38)</sup>. Despite the exclusion criteria that excluded those above the age of 60, there was a link between the ocular manifestations and the patients' ages, with a P-value of 0.026. Involvement of the eyes was higher in older participants and increased with age.

The environment, kind of occupation, seasons of the year, and duration of rheumatoid arthritis may all impact the incidence of these manifestations. The current study found no statistically significant relationship between these characteristics; however, Vignesh and Srinivasan, 2015 discovered an association with the duration of rheumatoid arthritis<sup>(23)</sup>.

Rheumatologists now routinely employ composite measurements to determine the severity of RA. The DAS28-ESR has been validated for measuring therapeutic response and is employed in most clinical

trials and daily practice<sup>(39)</sup>. The reliability and validity of this instrument in clinical studies have been thoroughly established. Despite emerging evidence of residual activity over time, DAS28 remains the most extensively used and established test in clinical practice. It also influences comorbidities, which may contribute to poor remission status or low disease activity, giving it a disproportionate weight compared to other formula components. CDAI, on the other hand, have lower residual activity, more comprehensible formulations, and more flexibility. The CDAI is also the composite index that does not need an acute phase response, which means it may be used to evaluate disease activity at any time and in any situation<sup>(40)</sup>. Although the DAS28-ESR is more objective than the CDAI and requires tools and a computer, both were used in parallel to evaluate the RA patients in this study. There was no significant statistical link between ocular involvement and disease activity. Albidri et al., 2016 found an association between dry eyes and active disease in a cross-sectional study of 103 patients with RA<sup>(41)</sup>.

In conclusion, Eye involvements of RA are a noticeable part of extra-articular manifestation, with the dry eye being the most apparent. Approximately one-third of those who have RA will experience a form of eye manifestation. The presence of anti-CCP antibodies has been associated with RA eye involvement. Those who tested positive for anti-CCP antibodies displayed more ocular manifestations. Eye involvement in RA patients is also related to RF and, to a lesser extent, patient age; it is more common in RF-positive patients and increases with age. The rheumatologists should have eye exams performed on all patients at the time of diagnosis and afterwards regularly to detect any early eye impairment.

## REFERENCES

1. Van der Woude D, Van der Helm-van Mil AHM. Update on the epidemiology, risk factors, and disease outcomes of rheumatoid arthritis. *Best Pract Res Clin Rheumatol* [Internet]. 2018;32(2):174–87. Available from: <https://doi.org/10.1016/j.berh.2018.10.005>
2. Radu AF, Bungau SG. Management of rheumatoid arthritis: An overview. *Cells* [Internet]. 2021 Apr 27 [cited 2022 Sep 23];10(11):301–15. Available from: <https://www.nature.com/articles/s41584-020-0409-1>
3. Lin YJ, Anzaghe M, Schülke S. Update on the Pathomechanism, Diagnosis, and Treatment Options for Rheumatoid Arthritis. *Cells*. 2020;9(4).

4. Jang S, Kwon EJ, Lee JJ. Rheumatoid Arthritis: Pathogenic Roles of Diverse Immune Cells [Internet]. Vol. 23, International Journal of Molecular Sciences. MDPI AG; 2022 [cited 2022 Sep 14]. p. 905. Available from: <https://doi.org/10.3390/ijms23020905>
5. Smolen JS, Aletaha D, McInnes IB. Rheumatoid arthritis. *Lancet* [Internet]. 2016 Oct 22 [cited 2022 Aug 8];388(10055):2023–38. Available from: [http://dx.doi.org/10.1016/S0140-6736\(16\)30173-8](http://dx.doi.org/10.1016/S0140-6736(16)30173-8)
6. Guo Q, Wang Y, Xu D, Nossent J, Pavlos NJ, Xu J. Rheumatoid arthritis: Pathological mechanisms and modern pharmacologic therapies. *Bone Res* [Internet]. 2018;6(1). Available from: <https://doi.org/10.1038/s41413-018-0016-9>
7. Shin YS, Choi JH, Nahm DH, Park HS, Cho JH, Suh CH. Rheumatoid factor is a marker of disease severity in Korean rheumatoid arthritis. *Yonsei Med J*. 2005;46(4):464–70.
8. Dai ZW, Wang ZH, Dong YY, Wu Y, Wang HL, Wang DG, et al. Diagnostic value of anti-citrullinated fibrinogen antibody in rheumatoid arthritis: A meta-analysis. *Int J Rheum Dis*. 2019 Apr 1;22(4):599–607.
9. Gavrilă BI, Ciofu C, Stoica V. Biomarkers in Rheumatoid Arthritis, what is new? *J Med Life*. 2016;9(2):144–8.
10. Yasmin R, Sarker H. Anti-CCP antibody in rheumatoid arthritis patients and its relation with disease severity. *BIRDEM Med J* [Internet]. 2021 Dec 30 [cited 2022 Jul 9];12(1):36–40. Available from: <https://www.banglajol.info/index.php/BIRDEM/article/view/57223>
11. Kokkonen H, Mullazehi M, Berglin E, Hallmans G, Wadell G, Rönnelid J, et al. Antibodies of IgG, IgA and IgM isotypes against cyclic citrullinated peptides precede the development of rheumatoid arthritis. *Arthritis Res Ther* [Internet]. 2011 [cited 2022 Jul 17];13(1). Available from: <http://arthritis-research.com/content/13/1/R13>
12. Van Der Linden MPM, Knevel R, Huizinga TWJ, Van Der Helm-Van Mil AHM. Classification of rheumatoid arthritis: Comparison of the 1987 American College of Rheumatology criteria and the 2010 American College of Rheumatology/European League Against Rheumatism criteria. *Arthritis Rheum* [Internet]. 2011;63(1):37–42. Available from: <http://onlinelibrary.wiley.com/journal/10.1002/>
13. Aletaha D, Neogi T, Silman AJ, Funovits J, Felson DT, Bingham CO, et al. 2010 Rheumatoid arthritis classification criteria: An American College of Rheumatology/European League Against Rheumatism collaborative initiative. *Arthritis Rheum* [Internet]. 2010 [cited 2022 Oct 9];62(9):2569–81. Available from: <https://pubmed.ncbi.nlm.nih.gov/20872595/>
14. Figus FA, Piga M, Azzolin I, McConnell R, Iagnocco A. Rheumatoid arthritis: Extra-articular manifestations and comorbidities. *Autoimmun Rev* [Internet]. 2021 Apr 1 [cited 2022 Aug 19];20(4):102776. Available from: <https://doi.org/10.1016/j.autrev.2021.102776>
15. Marcucci E, Bartoloni E, Alunno A, Leone MC, Cafaro G, Luccioli F, et al. Extra-articular rheumatoid arthritis. Vol. 70, *Reumatismo*. Page Press Publications; 2018. p. 212–24.
16. Bhamra MS, Gondal I, Amarnani A, Betesh S, Zhyvotovska A, Scott W, et al. Ocular Manifestations of Rheumatoid Arthritis: Implications of Recent Clinical Trials. *Int J Clin Res Trials* [Internet]. 2019;4(2):139. Available from: <https://doi.org/10.15344/2456->
17. Lamba N, Lee S, Chaudhry H, Foster CS. A review of the ocular manifestations of rheumatoid arthritis. *Cogent Med* [Internet]. 2016;3(1):1243771. Available from: <https://www.tandfonline.com/action/journalInformation?journalCode=oamd21>
18. Eldaly ZH, Saad SA, Hammam N. Ocular surface involvement in patients with rheumatoid arthritis: Relation with disease activity and duration. *Egypt Rheumatol*. 2020 Jan 1;42(1):5–9.
19. Artifoni M, Rothschild PR, Brézin A, Guillevin L, Puéchal X. Ocular inflammatory diseases associated with rheumatoid arthritis. *Nat Rev Rheumatol* [Internet]. 2014 Feb 10 [cited 2022 Sep 5];10(2):108–16. Available from: <https://pubmed.ncbi.nlm.nih.gov/24323074/>
20. Evren Kemer O. Dry eye in rheumatoid arthritis. *Int Ophthalmol Clin* [Internet]. 2017 [cited 2022 Aug 20];57(2):89–99. Available from: <https://pubmed.ncbi.nlm.nih.gov/28282316/>
21. Abd-Allah NM, Hassan AA, Omar G, Hamdy M, Abdelaziz STA, Abd El Hamid WM, et al. Dry eye in rheumatoid arthritis: relation to disease activity. *Immunol Med* [Internet]. 2020;43(2):92–7. Available from: <https://doi.org/10.1080/25785826.2020.1729597>
22. Kitazawa K, Inotmata T, Shih K, Hughes J-WB, Bozza N, Tomioka Y, et al. The Impact of ageing on dry eye disease's pathophysiology: A systematic review and meta-analysis. *Ocul Surf*. 2022 Jul 1;25:108–18.

23. Vignesh APP, Srinivasan R. Ocular manifestations of rheumatoid arthritis and their correlation with anti-cyclic citrullinated peptide antibodies. *Clin Ophthalmol* [Internet]. 2015 Feb 25 [cited 2023 Jan 29];9:393-7. Available from: <https://pubmed.ncbi.nlm.nih.gov/25750517/>
24. Kaur P, Singh Bal B, Singh B, Duggal A, Kaur I. To Study The Prevalence of Ocular Manifestations in Rheumatoid Arthritis And Their Correlation with Anti Cyclic Citrullinated Peptide Antibodies And Rheumatoid Factor. *IOSR J Dent Med Sci* [Internet]. 2016 [cited 2022 Aug 8];15(09):58-63. Available from: [www.iosrjournals.org](http://www.iosrjournals.org)
25. Pegu I, Puzari BS, Kakati S, Choudhury G. Ocular Manifestations in Rheumatoid Arthritis and their Co-Relation with Anti Cyclic Citrullinated Peptide Antibodies. *Int J Sci Res* [Internet]. 2018 [cited 2022 Aug 8];8. Available from: [www.ijsr.net](http://www.ijsr.net)
26. Fadhil R, Al-Dabbagh K. Prevalence and characteristics of eye involvement in patients with rheumatoid arthritis. *Zanco J Med Sci* [Internet]. 2017 Sep 1 [cited 2022 Aug 8];21(2):1708-14. Available from: <https://doi.org/10.15218/zjms.2017.024>
27. Tsubota K, Yokoi N, Shimazaki J, Watanabe H, Dogru M, Yamada M, et al. New Perspectives on Dry Eye Definition and Diagnosis: A Consensus Report by the Asia Dry Eye Society. *Ocul Surf*. 2017 Jan 1;15(1):65-76.
28. Berchicci L, Miserocchi E, Di Nicola M, La Spina C, Bandello F, Modorati G. Clinical features of patients with episcleritis and scleritis in an Italian tertiary care referral centre. *Eur J Ophthalmol*. 2013;24(3):293-8.
29. Thong LP, Rogers SL, Hart CT, Hall AJ, Lim LL. Epidemiology of episcleritis and scleritis in urban Australia. *Clin Exp Ophthalmol*. 2020;48(6):757-66.
30. Zlatanović G, Veselinović D, Cekić S, Živković M, Dordević-Jocić J, Zlatanović M. Ocular manifestation of rheumatoid arthritis-diff event forms and frequency. *Bosn J Basic Med Sci* [Internet]. 2010 Nov 1 [cited 2022 Sep 15];10(4):323-7. Available from: <https://doaj.org/article/cd3846ebb1bb4082aa876b31591c70f3>
31. Weiss M, Molina R, Ofoegbuna C, Johnson DA, Kheirkhah A. A review of filamentary keratitis [Internet]. *Survey of Ophthalmology* Jan 1, 2022 p. 52-9. Available from: <https://scholars.uthscsa.edu/en/publications/a-review-of-filamentary-keratitis>
32. Wu Y, Wang C, Wang X, Mou Y, Yuan K, Huang X, et al. Advances in Dry Eye Disease Examination Techniques [Internet]. Vol. 8, *Frontiers in Medicine*. 2022. p. 826530. Available from: [www.frontiersin.org](http://www.frontiersin.org)
33. Kervick GN, Pflugfelder SC, Haimovici R, Brown H, Tozman E, Yee R. Paracentral Rheumatoid Corneal Ulceration: Clinical Features and Cyclosporine Therapy. *Ophthalmology*. 1992;99(1):80-8.
34. Charpentier S, Keilani C, Maréchal M, Friang C, De Faria A, Froussart-Maille F, et al. Corneal Haze post photorefractive keratectomy. *J Fr Ophtalmol*. 2021 Nov 1;44(9):1425-38.
35. Kim SH, Jeong SH, Kim H, Park EC, Jang SY. Development of Open-Angle Glaucoma in Adults with Seropositive Rheumatoid Arthritis in Korea. *JAMA Netw Open* [Internet]. 2022 Mar 1 [cited 2022 Aug 6];5(3): E223345. Available from: <https://jamanetwork.com/>
36. Avouac J, Gossec L, Dougados M. Diagnostic and predictive value of anti-cyclic citrullinated protein antibodies in rheumatoid arthritis: a systematic literature review. *Ann Rheum Dis* [Internet]. 2006 Jul 1 [cited 2022 Aug 11];65(7):845-51. Available from: <https://ard.bmj.com/content/65/7/845>
37. Payet J, Gouvestre C, Bialé L, Avouac J, Wipff J, Job-Deslandre C, et al. Anticyclic citrullinated peptide antibodies in rheumatoid and non-Rheumatoid rheumatic disorders: Experience with 1162 patients. *J Rheumatol* [Internet]. 2014 Dec 1 [cited 2022 Oct 24];41(12):2395-402. Available from: <https://www.jrheum.org/content/41/12/2395>
38. Gipson IK. Age-related changes and diseases of the ocular surface and cornea. *Investig Ophthalmol Vis Sci*. 2013 Dec 1;54(14): ORSF48-53.
39. Leung YY, Cheung P, Canhão H, Rodrigues AM, Gregório MJ, Dias SS, et al. Common Evaluations of Disease Activity in Rheumatoid Arthritis Reach Discordant Classifications across Different Populations. *Front Med* [Internet]. 2018 [cited 2022 Dec 22];5:40. Available from: [www.frontiersin.org](http://www.frontiersin.org)
40. Santos IA, de Oliveira RDR, Almeida SCL, Vargas-Santos AB, Amorim RBC, Gomides APM, et al. Comparison of rheumatoid arthritis composite disease activity indices and residual activity in a Brazilian multicenter REAL study. *PLoS One*. 2022 Sep 1;17(9 September).
41. Albidri K, Mohammad NK, Isho F, Al-Bedri K, Al-Quriashi NKM, Gorial FI, et al. Ocular Manifestations in Rheumatoid Arthritis: A Descriptive Cross-Sectional Study from Iraq. *J Nat Sci Res* [Internet]. 2016 [cited 2022 Sep 5];6(8):118-23. Available from: [www.iiste.org](http://www.iiste.org)